



Sentara Norfolk General
PI: Dr. David Dexter



SITE 006

Sentara

Dr. Dexter

Patient 006-007. (RLB)



62 year old male with C6 disease

Past Medical History

Rheumatoid Arthritis

Diabetic

Peripheral Neuropathy

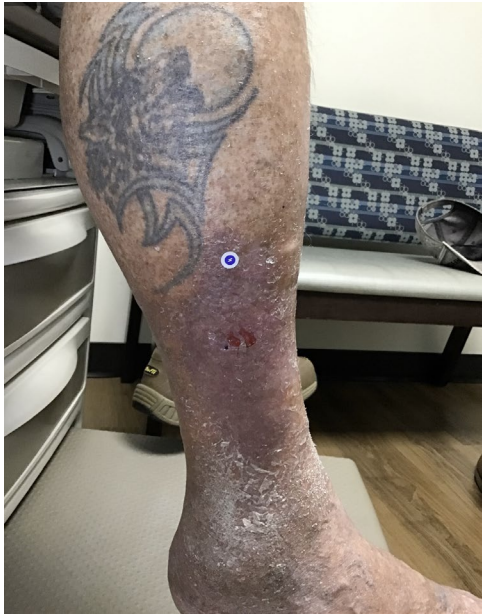DVT with CVI

006-007 Implant Date 8/10/2022

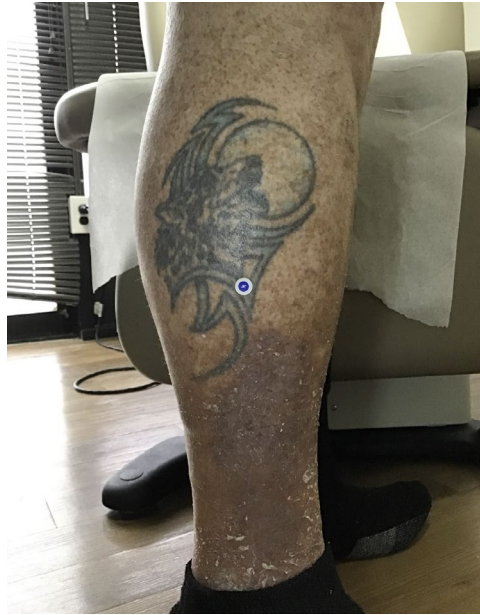- Surgical Procedure
 - On 8/10/2022 patient underwent placement of a 9 mm VenoValve into the right femoral vein
 - Patient had primary closure of vein.
- Post-Op Notes
 - Patient was discharged and treated with Lovenox 120mg bid
 - Developed Seroma and needed drainage 18 days post op
- Follow-up notes

Follow up data 006-007

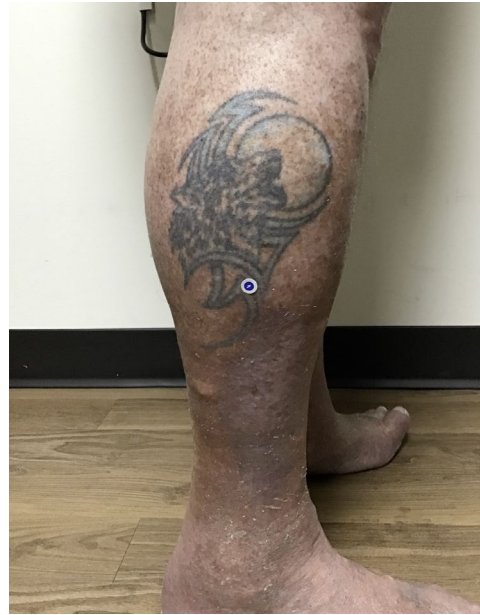
Quality of Life Measures				
	Baseline	3 months	6 months	12 months
rVCSS	16	8	6	5
EQ5D (health today)	50	70	70	73



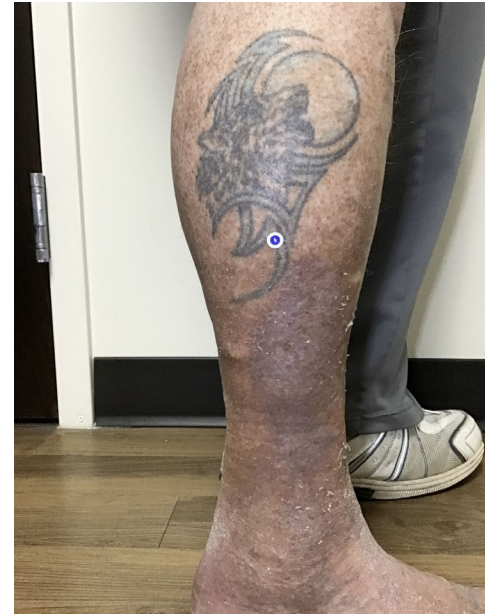BASELINE



30 DAYS



3 MONTHS



6 MONTHS

1 YEAR

Patient 006-010 (BMR).



65 year old male with C6 disease

Past Medical History

Rheumatoid Arthritis

Diabetic

Peripheral Neuropathy

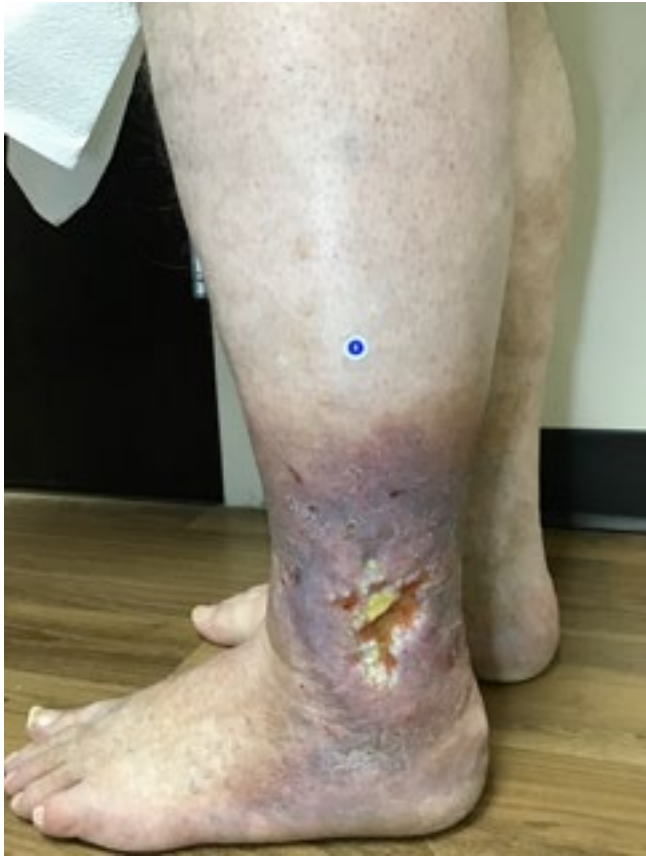DVT with CVI

006-007 Implant Date 12/16/2022

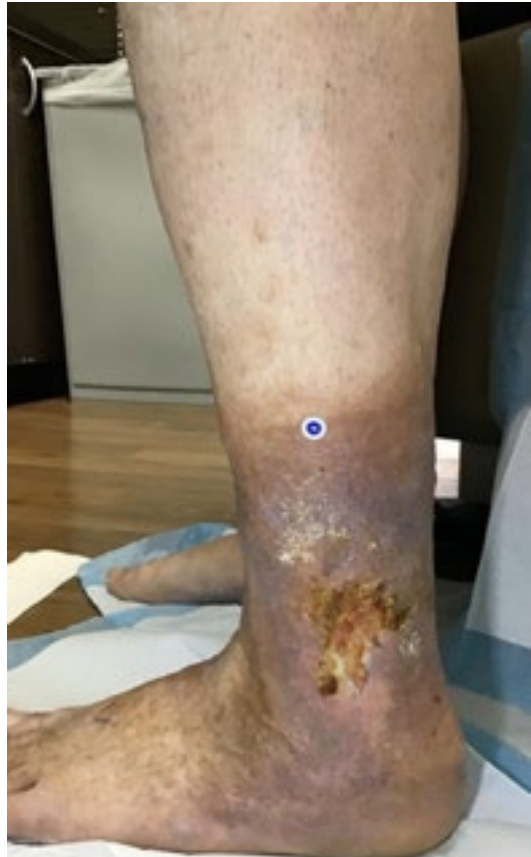- **Surgical Procedure**
 - On 12/16/2022 patient underwent placement of a 9 mm VenoValve into the left femoral vein
 - Patient had primary closure of vein.
- **Post-Op Notes**
 - Patient was discharged and treated with Lovenox 120mg bid
 - Developed a hematoma and needed drainage 13 days post op
- **Follow-up notes**

Follow up data 006-010

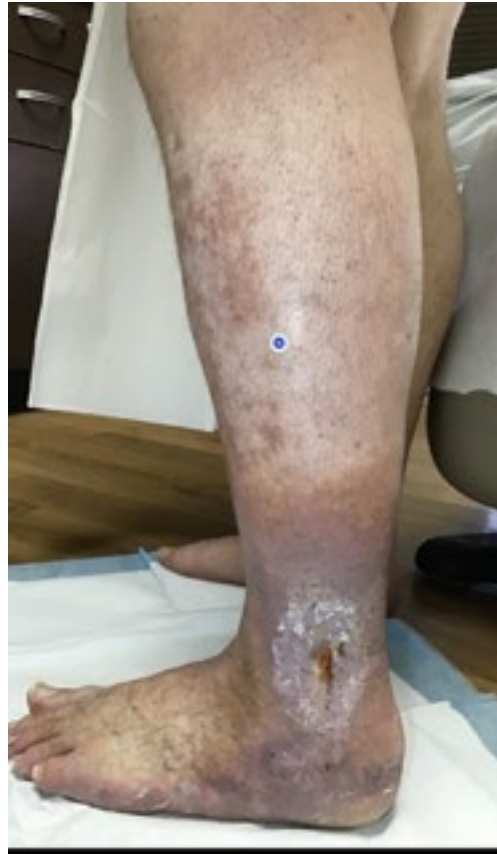Quality of Life Measures				
	Baseline	3 months	6 months	12 months
rVCSS	24	20	15	n/a
EQ5D (health today)	70	70	60	n/a



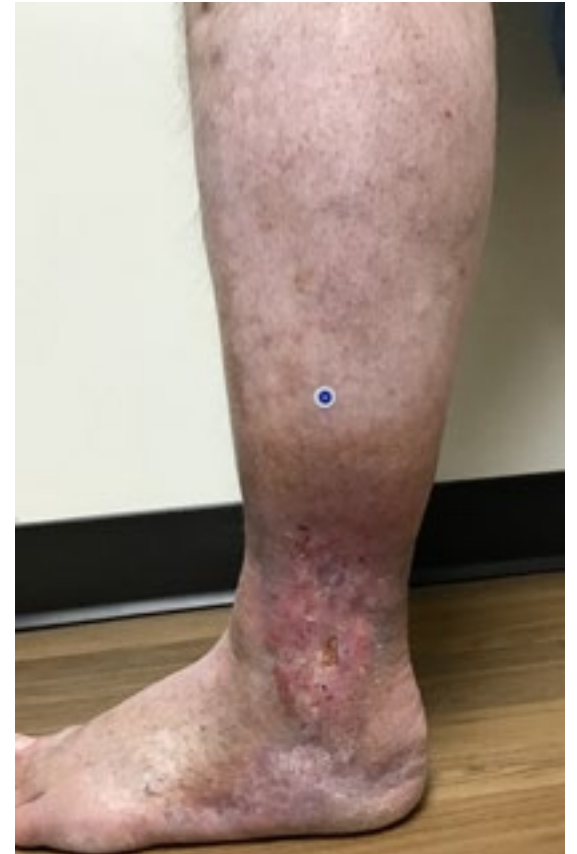BASELINE



30 DAYS



3 months



6 months

Surgical Technique

- Mid Thigh Access
- Vein Dissection
- Venous Tributaries
- Vein Closure

Post Operative Considerations

- Compression
- Anticoagulation
- Sequential Compression
- Post Operative Activity