



Yale University
School of Medicine

Yale
NewHaven
Health

Deep Venous Reflux SAVVE STUDY

Surgical Antireflux Venous Valve Endoprosthesis

Cassius Iyad Ochoa Chaar MD, MPH, MS, FACS

Associate Professor of Surgery

Yale School of Medicine

November 16th, 2023



Yale University
School of Medicine

Disclosures

Yale
NewHaven
Health

➤ Patent related to IVC filter retrieval device



Yale University
School of Medicine

Deep Venous Reflux

Yale
NewHaven
Health

Incidence and Significance of Deep Venous Reflux in Patients Treated with Saphenous Vein Ablation

Keyuree Satam,¹ Afsha Aurshina,² Haoran Zhuo,³ Yawei Zhang,⁴ Jonathan Cardella,² Edouard Aboian,² Britt Tonnessen,² Raul J. Guzman,² and Cassius Iyad Ochoa Chaar,² New Haven, Connecticut; Beijing, China; and New Haven, CT, United States

- 20% of patients undergoing vein ablation for superficial venous reflux have deep venous reflux
- Patient with concomitant deep venous reflux are more likely to have complication



Yale University
School of Medicine

Deep Venous Reconstructive Surgery for Reflux (DVRSR)

Yale
NewHaven
Health

Systematic review and meta-analysis of deep venous reflux correction in chronic venous insufficiency

Oscar Maleti, MD,^a Massimiliano Orso,^b Marzia Lugli, MD,^a and Michel Perrin, MD,^c
Modena and Perugia, Italy; and Chassieu, France

- A variety of techniques: External valvuloplasty, internal valvuloplasty, banding, allograft, vein transplant, vein transposition, neovalve

DVRSR was performed by a few specialized teams either for primary etiology or post-thrombotic syndrome

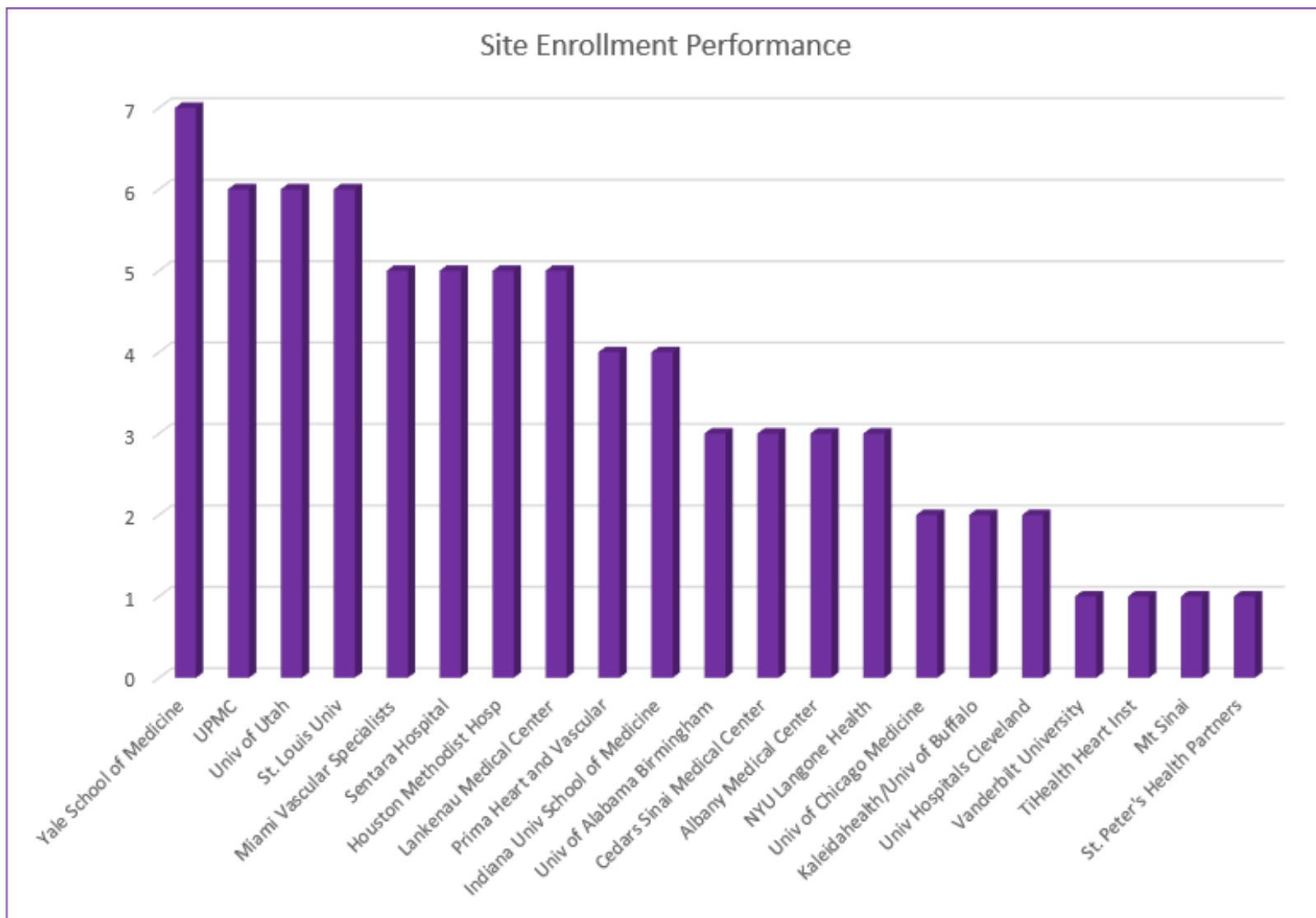
In fact, this type of surgery has never been widely applied and remained the prerogative of few centers worldwide.⁷² It is unclear which are the reasons for this



Yale University
School of Medicine

Yale – Site #4

Yale
NewHaven
Health





Yale University
School of Medicine

Site #4 – Subject #4

Yale
NewHaven
Health



**66 year old male with
C6 disease**

Past Medical History

Hyperlipidemia

PAD

DVT

Osteo arthritis



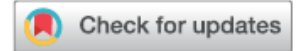Yale University
School of Medicine

MR. 44

Yale
NewHaven
Health

From the New England Society for Vascular Surgery

Endovascular iliac vein recanalization after Palma procedure for treatment of recalcitrant venous ulcer

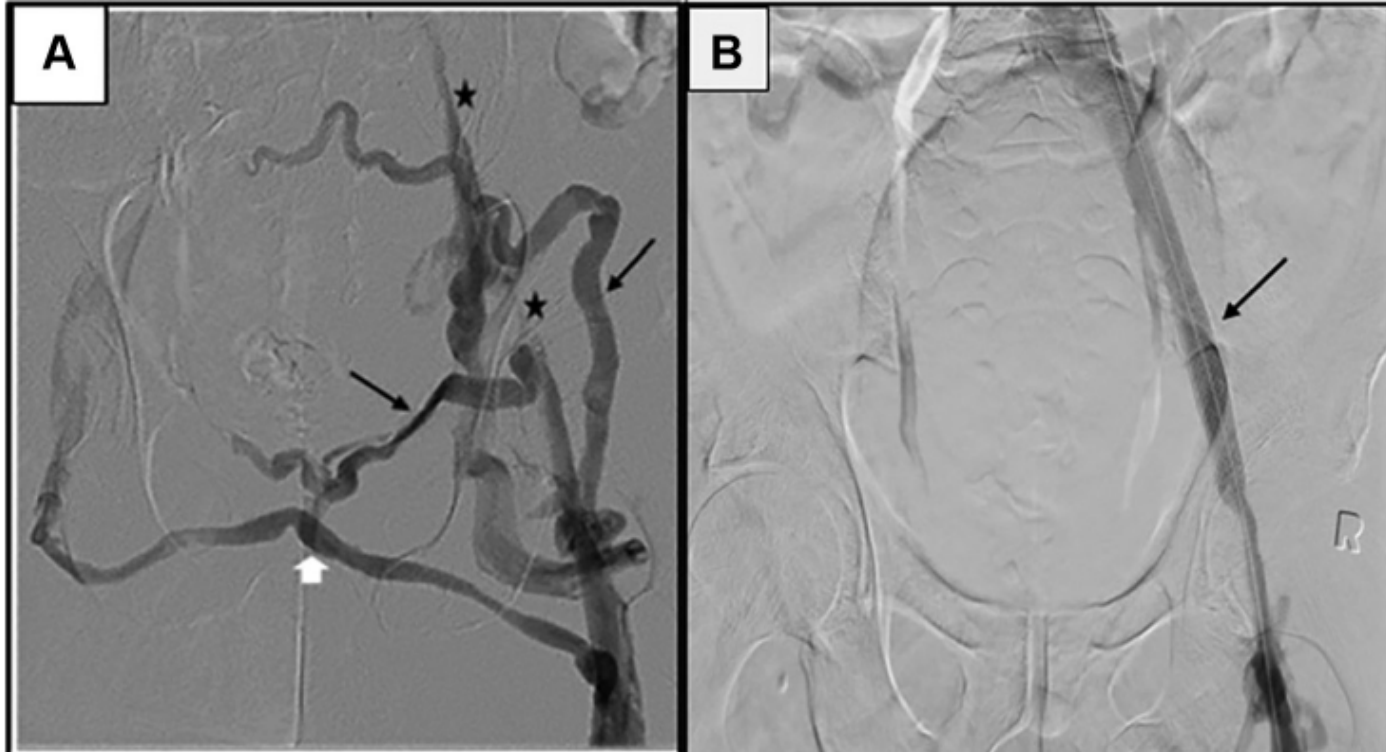


Afsha Aurshina, MBBS,^a Hamid Mojibian, MD,^b and Cassius Iyad Ochoa Chaar, MD, MS, FACS,^a
New Haven, Conn

- Provoked DVT after hospitalization for 3rd degree burn at age 18
- Non-healing intermittent leg ulcer for almost 25 years
- Underwent a Palma vein bypass that was patent



MR. 44



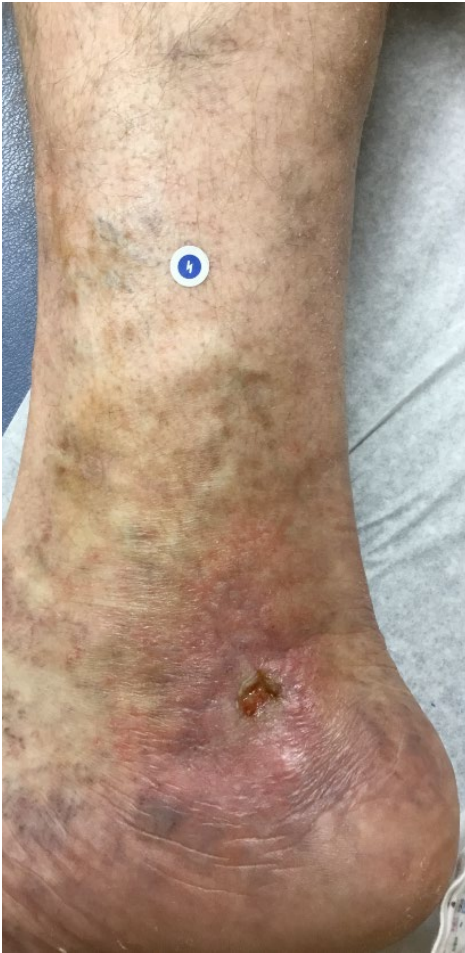- Healed ulcer in 3 months
- Remained healed for 4 years
- Recurred with small ulcer at 5 years



Yale University
School of Medicine

MR. 44

Yale
NewHaven
Health



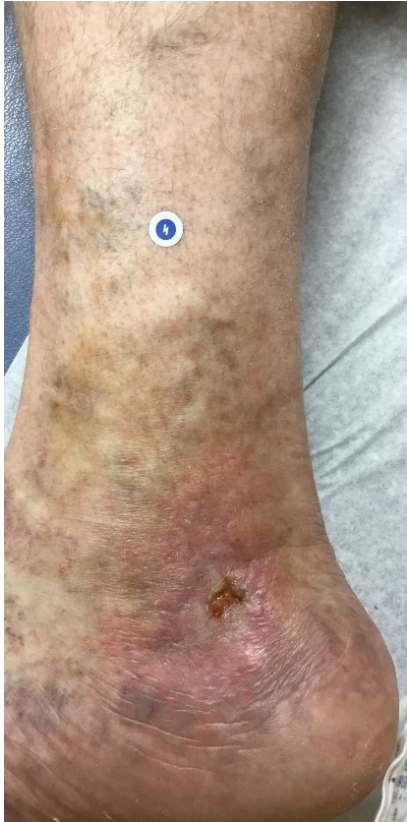- Venous Clinical Severity Score = 18
(VCSS Range = 0-30)
- Treated with Compression stockings
with various grades and forms
for 3 years
- Active and limited with walking and
required intermittent OTC pain meds



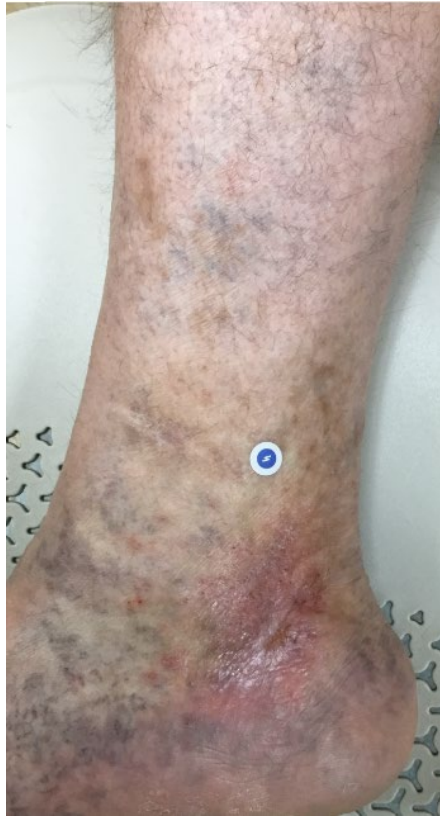Yale University
School of Medicine

MR. 44

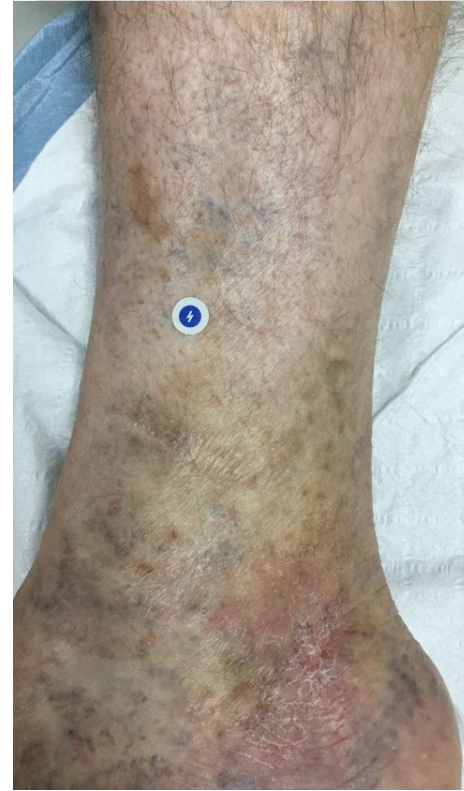Yale
NewHaven
Health



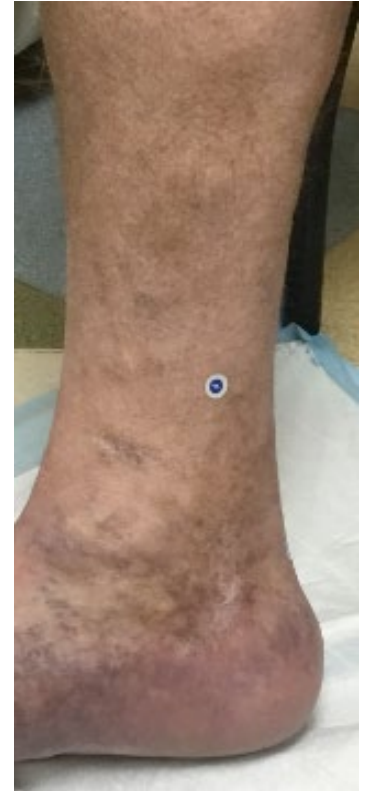BASELINE



3 MONTHS



6 MONTHS



1 YEAR



Yale University
School of Medicine

MR. 44

Yale
NewHaven
Health

Quality of Life Measures

	Baseline	3 months	6 months	12 months
rVCSS	18	8	5	5
EQ5D (health today)	61	73	100	90



Yale University
School of Medicine

Conclusion

Yale
NewHaven
Health

- Deep Venous Reflux is Very common
- Deep Venous Reflux has no current, standardized surgical treatment
- SAVVE trial brought unique therapeutic opportunities to my patients and improved their Quality of life



Yale University
School of Medicine

Yale
NewHaven
Health

THANK YOU